

Original Article

Shikher Shrestha

FCPS neurosurgery

National Institute of Neurological and Allied Sciences
Bansbari, Nepal

Suresh Bishokarma, MS

Mch Neurosurgery resident

National Institute of Neurological and Allied Sciences
Bansbari, Nepal

Upendra Prasad Devkota

FRCS (Glasgow), FRCS Edin (Ad hominem), FCSHK
(Hong Kong), FNAMS (NAMS) Neurosurgeon-in-Chief
National Institute of Neurological and Allied Sciences
Bansbari, Nepal

Address for correspondence:

Shikher Shrestha, FCPS neurosurgery
National Institute of Neurological and Allied Sciences
Bansbari, Nepal
P. O. Box: 3711
Tel : +977-1-4373850
Fax: +977-1-4370779
Email: shresthashikher@gmail.com

Date submitted: 29/5/2018

Date accepted: 25/8/2018

Contoured Loop and Modified Wiring Technique for occipitocervical Fixation - A Safe and Efficacious Option

To study the safety and efficacy of contoured loop and modified wiring techniques for occipitocervical fixation. Retrospective study among 15 patients who underwent occipitocervical fixation from Jan 2011-16 were reviewed. Contoured loop was wired at 2 points in occiput and 4 different points, 2 on either side to percutaneously passed K wire through the spino laminar junctions of C2 and C3. Additional fusion with onlay autologous graft from either iliac crest or ribs was done. Various parameters studied were patient's demography, causes of instability, change in neurological function, complications and radiographic outcome. Six had basilar invagination, 4 had traumatic atlantoaxial subluxation, 4 had osodontoidium and 1 had Rheumatoid arthropathy. There was improvement in Frankel grade from C to D in 6 and from D to E in 5 patients. Radiological union at 6 months was observed in all 15 cases. Two patients had surgical site infection. Dislodgement of K wire was found in 4 cases (26.66%) by which time radiological union had already taken place. The approximate cost of instrumentation was 100 dollars for each patient. Conclusions. Contoured rod and modified wiring occipitocervical fixation technique are relatively a safe, cheap and technically easy alternative for the management of occipitocervical instability.

Keywords: Occipitocervical fixation, Osodontoidium Contoured Loop, Modified Wiring Technique, Basilar invagination.

Occipitocervical Fixation has been historically used for treating Occipitocervical Instability. Various pathologies resulting in instability includes trauma, tumors, congenital malformation, degenerative conditions, rheumatological disease and infection. Occipitocervical Instability was considered inoperable and terminal in early 1900s. In 1927, Forrester first described Occipitocervical fixation using Fibular and Tibial onlay grafts with Halo immobilization.⁹ Over the time various techniques evolved, that included Harshill-Ranford loop ⁷ in 1986, occipito-axis posterior wiring

and fusion in 1993 by Jain et. al.⁴ and in the same year, Rod and wire system by Sonntag and Dickman ⁸. In 1998, Faure¹ invented Hook and Rod Occipital Clamp system and recently occipital plate, rod and screw systems are widely used for fixating occipitocervical instability. We, however are presenting our aged technique, we have been using in our institute for occipitocervical fixation, which has short learning curve for the operating surgeon and is safe with desirable result and cheap for the patients with occipitocervical instability.

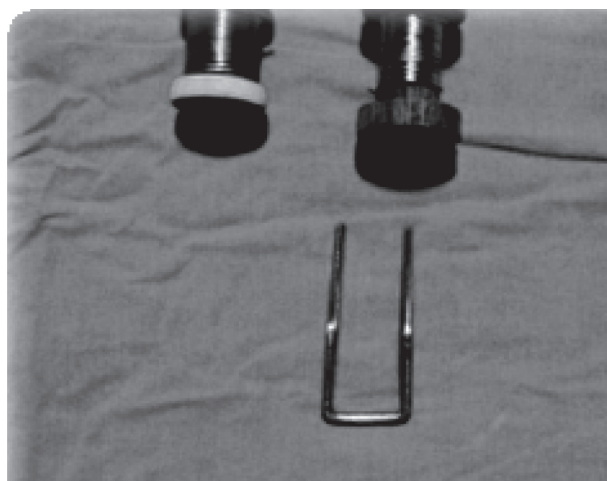


Figure 1 : Constructs used in Occipitocervical fixation: Stainless steel wire, Contoured rod tailored for patient's spine and K-wire

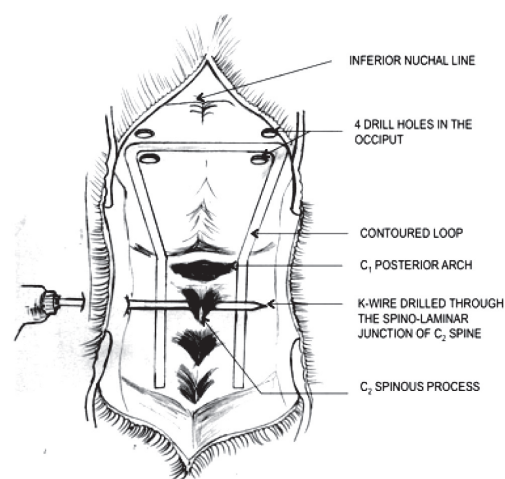


Figure 2 : Drawing illustrating placement of contoured rod in spine and percutaneous passage of K-wire through spinous process of C2

Methodology:

We collected a retrospective data of 6 years starting January 2010 to January 2017. All patients with occipitocervical instability were included. Various outcome measures like postoperative neurological improvement, fusion achieved and complications encountered during the procedure were taken into consideration. The mean duration of follow up was 6 months post operatively. We describe the hybrid method of modified contoured rod, which is wired in Occiput at 2 points and the limbs of rod wired to the K wire passed percutaneously through the base of spinous processes of C2 and C3 and 2 points on either side and at those 2 levels respectively.

Our technique

Patients with craniovertebral junction anomaly, either congenital or traumatic, often discovered after trivial trauma with impaired neurology were included for the procedure. The contraindication was when the impairment was severe enough to cause respiratory distress.

Patient is kept in Crutzfield traction for 48 hours, evaluated for change in neurology and radiological evidence of reduction. Transoral odontoidectomy is done for severe anterior impingement by the odontoid process. Contoured stainless steel loop as designed by the senior author was made locally using stainless steel rod and is customised in length, width and angulation (**Figure 1**) as per the patient anatomy studied on post traction cervical spine x-ray with room for minor modification intraoperatively. Standard midline exposure of the occiput and the upper cervical vertebrae is done in prone position. Contoured loop was wired at 2 points in occiput near the inferior nuchal line by making 2 small drill holes on either side of midline (**Figure 2**).

The vertical limbs of the contoured loop were secured with percutaneously passed K wire through the spino-laminar junctions of C2 and C3 and they are wired snugly with each other, thus avoiding sublaminar placement of wires (**Figure 3**). Additional fusion with onlay autologous graft from iliac crest or ribs was done after morcellating and mixing with some blood from operative site. Closure was done without drain in situ. Post-operative, Philadelphia collar was used for 3 months and collar removed after the evidence of radiological fusion on check x-ray on outpatient follow up was seen (**Figure 4**).

Result:

There were total of 15 patients, out of which 9 (60%) were male and 6 (40%) female. The mean age of presentation was 27.13 ± 16.03 years (range of 4 to 56 years). The various reasons for occipitocervical instability in our series were Basilar invagination in 6 (40%), Trauma in 4 (26.66%) (motor vehicle accident in 2 and injury due to fall in 2), Osodontoideum in 4 (26.66%) and Rheumatoid arthritis in 1 (6.66%) case. The duration of symptomatology before presentation ranged from 7 days to 15 years.

The presenting symptoms were cervical pain in 8 (53.33%), weakness of extremities in 7 (46.66%) and Sensory paresthesia in 2 (13.33%) cases. Feature suggestive of compressive myelopathy was evident in 10 (66.66%) cases. Frankel grading was done preoperatively and its assessment at 6 months follow up was done. Six patients had Frankel C, 5 had Frankel D and 3 had Frankel E at the time of presentation; which changed to Frankel D, E and E respectively at 6 months follow up. Fusion was reconfirmed by repeat X-ray C spine. One patient

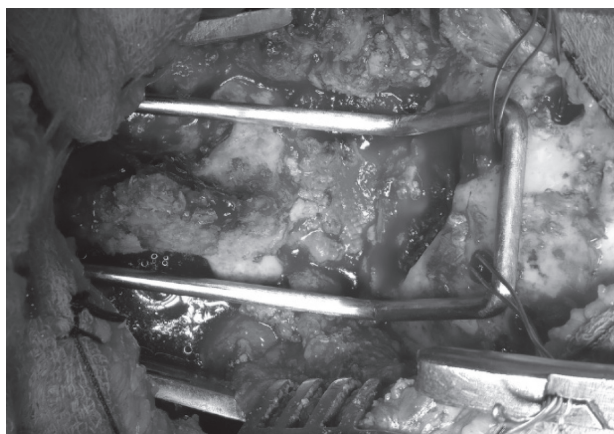


Figure 3 : Intraoperative picture depicting the placement of contoured rod fixed to occiput via SS wire passed through 2 burrs on either side of the horizontal limb of the contoured rod

with Osodontoidium, who was symptomatic after having sustained trivial trauma while on outdoor sport succumbed to the respiratory complication due to severe preoperative cord changes he had. Other post-operative complications included superficial surgical site infection in 2 patients, which was managed using drainage, antibiotics and secondary closure. Late Dislodgement of K wire was observed in 4 patients, by which time, the fusion had already occurred and the K wire used was removed under local anesthesia. There was no dural tear or post-operative neurological deterioration.

Discussion

The complex anatomy and the unique biomechanics in the region of CV junction made this area a surgical challenge for decades. Dating back to time when Forester first reported the surgical fusion, many historical developments have evolved specially in terms of indications, classifications, operative approaches, instrumentation techniques, and fusion rates with various surgical procedures. The techniques have evolved from simple onlay grafts with or without wire stabilization to more complex futuristic new generation plate/rod hybrid constructs with polyaxial screws in an attempt to maximize patient's benefit in terms of surgical recovery. No wonder, the techniques are growing in complexities and the cost factor ever increasing with each recent development with more or less plateau in the outcome that a procedure has to offer. With newer complex modality, the surgical adjuncts like detailed understanding of 3D surgical anatomy and intraoperative image guidance in order to avoid inadvertent intraoperative injuries are incorporated.

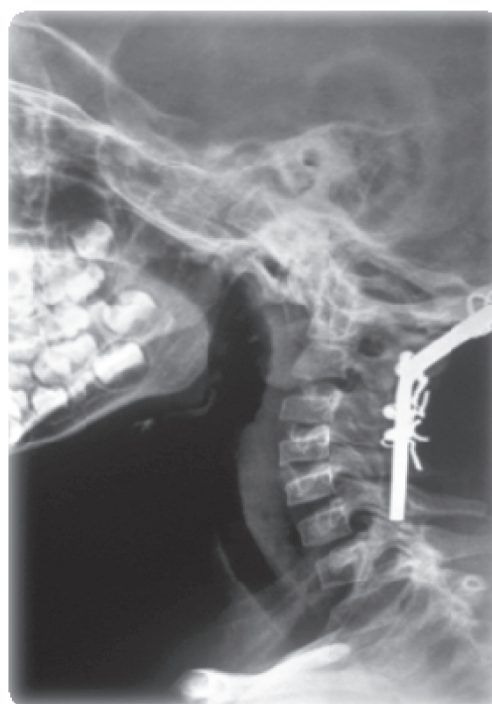

Figure 4 : X ray lateral view of Cervical spine showing implants in situ

The surgical learning curve henceforth is a steep curve. The cost keeps on increasing and would be difficult for a patient of third world country without any government health insurance back up.

A systematic review by Winegar et. al.¹¹ reports no articles stronger than Class IV evidence. This is a single center study and the number of cases is small. We had 14 cases considered in total over a duration of 5 years. The mean age of presentation was 32.3 years (range of 4-56 years). The various retrospective case series taking into consideration of onlay/wires and rod/wires construct reported total patients in different numbers. The number of patients reported varied widely ranging from 4 in Ransford's series to as high as 150 cases by Moskovich et. al.⁶ In a systematic review by Winegar et. al.¹¹, 34 articles including 799 patients were considered with mean age \pm SD of 54.3 \pm 17.2 (range 18-87 years) with indications of surgery being inflammatory disease in 396 patients (49.6%), congenital anomalies in 84 (10.5%), for tumor in 67 (8.4%) and for trauma in 63 (7.9%). In our own series, the various indications were congenital anomalies including basilar invagination and osodontoideum in 9 (64.3%), trauma in 4 (28.6%) and rheumatoid arthritis in 1 (7.1%) case.

The neurological recovery in our series was in 78.5%, quite comparable to the other series (Table 1) with fixation using rod/wires and onlay/wires construct. Wertheim and Bohlman¹⁰, 1987 reported in their retrospective series

Contoured loop fixation

Profile	Our Study	Winegar CD et al 2010	Moskovich et al.2004	Fehling et al. 1993	Ransford et al. 1996	Malcolm et al.1994
Total patients	15	799 (34 articles)	150	16	4	43
Mean age	27.13±16.03	54.3±17.2				
Range	4-56	18-87	-	-	-	
Instrumentation	Contoured loop/wire	-	Rod/Wire	Rod/wire	onlay/wires	Rod/wire
Neurological improvement	73.3%	-	18%	100	-	58%
Surgical complication	13.3		7%	12	-	
Fusion Status	13/14	93.33% W/R > S/P > Onlay	-	-	100% fusion	-
Adverse events		S/P > R/W > S/R	-	-	-	-
Instrument failure	6.66%	Posterior wiring (10.1%) Onlay>S/P >R/W >S/R	-	-	-	-
Mortality	6.66	Surgery related 0.6% Perioperative 3.75%	10%	-	-	-

Table 1: Comparison with various study^{2,5,6,7,11}

of 13 cases the neurological improvement of 75%; and in various other series, it has been reported ranging from 30% by Grob et. al.³ (1991) to 100% by Fehlings et. al.² (1993). Ransford et. al.⁷ 1986, in their case report of 3 have reported the neurological improvement in 100% of cases. The trend in neurological recovery in a way is related to the number of patients into consideration and the type of construct used in various studies, though there was no statistical significant difference in recovery when various pathologies for instability were considered in the systematic review. In the same review, out of 521 cases which provided information on neurological status, 336 (64.5%) cases showed neurologic recovery. But this included data using rod/screw and plate/screws construct as well.

Fusion was achieved in 14 (93.33%) cases, as evident clinically from disappearance of pain and radiologically

by arthrodesis seen on check x-rays obtained during 3 months follow up. Fusion status from 544 patients in the systemic analysis⁶ also showed successful fusion in 517 (93.33%), with highest rate of successful arthrodesis in wiring/rod construct - 95.9% (187 of 195). Dynamic x ray was not done as due to reduction in 50% of mobility on either side in cases of occipitocervical fixation, will not allow to give a picture reflective enough to show the mobility between the segments fused. Furthermore, there was fear of external distractive force provoked during flexion/extension view during dynamic x-ray, which might cause the implant to break. We also kept the patient in collar for 3 months post procedure, to avoid excessive movement in neck. Other limitation we had was failure to address 3 column fixations, which holds true for other constructs using occipito-cervical fixation.

Instrumentation failure in our series was in 1(6.66%) case, where there was breakage of wire. Dislodgement of K wire was seen in 4 (26.66%) cases, by which time the fusion had already occurred and the dislodged K wire was removed without any complication under local anesthesia. The systematic review by Winegar et. al¹¹ showed failure of instrumentation in 21% (38 of 178) cases, while instrumentation failure following wiring and onlay bone grafting occurred in 14 (100%) of 14 cases, followed by screw/plate techniques 8 (26.67%) of 30, wiring/rod techniques 13(13.54%) of 96 and screw/rod techniques 3 (7.89%) of 38.

The surgical complication in the form of surgical site infection in 2 (13.33%) cases. Both the cases had undergone transoral odontoidectomy with occipitocervical fixation. This was managed with drainage and antibiotic coverage and made subsequent recovery with prolonged duration of hospital stay. Various surgical complications in different form have a reported incidence of 11.79% (23 of 195) in the systematic review,¹¹ which included vascular injury and significant blood loss in 2 (8.7%) of 23 cases, thecal sac injury and subsequent CSF leak in 1 (4.3%) of 23 cases. We however did not encounter such event and should be remote in our procedure followed due to the remote anatomy of vessels and thecal sac while wiring the limb of contoured loop with the K wire that is passed through the base of the spinous process.

There was 1 (6.66%) mortality. This was a case of a 14-year-old boy with osodontoidium manifesting after trivial trauma with difficulty in walking, breathing and swallowing. He succumbed to death due to prolonged ventilator dependence secondary to brainstem involvement he had because of the impinging osodontoidium.

There is no enough data comparing cost of various constructs. The cost for this locally made construct in our series however does not exceed 100 Dollars. This in fact with the comparable fusion rates and the rate of neurological recovery is efficacious for the average patients in our set up. Poor patients have to pay from their pockets as there is no insurance coverage.

Conclusion:

Contoured rod and modified wiring occipitocervical fixation despite having its own limitations, is a safe, cheap and technically easy alternative for the management of occipitocervical instability in developing nation. With this alternative technique of wiring the rods of the contoured loop to the K wire with onlay graft, we have been able to achieve comparable fusion rate and neurological recovery

as in other studies using different available construct with much cheaper yet safer way, even today when the paradigm is shifting towards more and more complicated constructs.

References:

1. Faure A, Monteiro R, Hamel O, Raoul S, Szapiro J, Alcheikh M, Bord E, Robert R. Inverted-hook occipital clamp system in occipitocervical fixation. **J Neurosurg** 97:135–141, 2002
2. Fehlings MG, Errico T, Cooper P, Benjamin V, DiBartolo T. Occipitocervical fusion with a five-millimeter malleable rod and segmental fixation. **Neurosurgery** 32:198-208, 1993
3. Grob D, Dvorak J, Panjabi M, Froehlich M, Hayek J. Posterior occipitocervical fusion. A preliminary report of a new technique. **Spine** 16 (3 Suppl):S17–S24, 1991
4. Jain VK, Takayasu M, Singh S, Chharbra DK, Sugita K. Occipital-axis posterior wiring and fusion for atlantoaxial dislocation associated with occipitalization of the atlas. Technical note. **Journal of neurosurgery** 79 (1):142-4, 1993
5. Malcolm GP, Ransford AO, Crockard HA. Treatment of non-rheumatoid occipitocervical instability Internal fixation with the Hartshill-Ransford loop. **J Bone Joint Surg Br** 76 (3):357-66, 1994
6. Moskovich R, Crockard HA, Shott S, Ransford AO. Occipitocervical stabilization for myelopathy in patients with rheumatoid arthritis Implications of not bone-grafting. **J Bone Joint Surg Am** 82:349–65, 2000
7. Ransford AO, Crockard HA, Pozo JL, Thomas NP, Nelson IW. Craniocervical instability treated by contoured loop fixation. **The Journal of bone and joint surgery Br** 68 (2):173-7, 1986
8. Sonntag VK, Dickman CA. Craniocervical stabilization. **Clin Neurosurg** 40:243-272, 1993
9. Vender JR, Rekitto AJ, Harrison SJ, McDonnell DE. The evolution of posterior cervical and occipitocervical fusion and instrumentation. **Neurosurg Focus** 16 (1):E9, 2004
10. Wertheim SB, Bohlman HH. Occipitocervical fusion. Indications, technique, and long-term results in thirteen patients. **J Bone Joint Surg Am** 69:833–6, 1987
11. Winegar CD, Lawrence JP, Friel BC, Fernandez C, Hong J, Maltenfort M, et al. A systematic review of occipital cervical fusion: techniques and outcomes. **J Neurosurg Spine** 13 (1):5-16, 2010