

Original Article

Yam B Roka, MS, MCh

Department of Neurosurgery  
Neuro Cardio and MultiSpeciality hospital  
Biratnagar, Nepal

Address for correspondence:

Yam B Roka, MS, MCh  
Department of Neurosurgery  
Neuro Cardio and MultiSpeciality hospital  
Biratnagar, Nepal  
Email: dryamroka@yahoo.com

Received, 9 February, 2017

Accepted, 17 February, 2017

## Review of the History of Materials Used With Experience with Bone Cement Cranioplasty

Cranioplasty is the surgical repair of cranial defect or deficiency of the skull with a aim for functional and cosmetic improvement. Inorganic and organic materials have both been used for cranioplasty with the ideal cranioplasty material is yet to be made or discovered with present focus of research on molecular biology. This article does a brief review of the history of materials used and discusses the results of the use of bone cement cranioplasty (BCC) in this centre. A total of 61 cases were included in the study with the majority being males (44 cases). Road traffic accident was the most common initial cause of injury (45 cases), followed by fall (10 cases) and physical assault in the rest. On admission and based on the GCS based head injury classification the majority were in the severe head injury type (GCS<8) in 44 cases followed by moderate head injury in the rest. The majority of the decompressive craniectomy was done on the left side (32 cases) followed by right (22 cases) and bilateral in 7 cases (including single flap bifrontal in 5 cases). In our centre as for other centres in Nepal and developing countries, bone cement remains the best, safest, cheapest choice along with autologous graft for cranioplasty.

**Key Words:** cranioplasty, bone cement, neurosurgical history

Cranioplasty is the surgical repair of cranial defect or deficiency of the skull with a aim for functional and cosmetic improvement. The history of cranioplasty dates back to 3000 B.C.<sup>1</sup> although the first documentation was done by Fallopius using gold and van Meekeren using bone graft.<sup>30</sup> Cranioplasty materials took a leap forward during the first and second world wars where there was a great demand due to the war related injuries. Inorganic and organic materials have both been used for

cranioplasty with no consensus as to which is the better one.<sup>18</sup> The ideal cranioplasty material is yet to be made or discovered and the characteristics desirable are listed in **Table 1**.<sup>3</sup> The present focus of research has shifted to molecular biology to regenerate the bone using the patients own tissue. Use of 3-D printers has also revolutionized the technique of cranioplasty in terms of the exact shape, anatomical curvature, cosmetic appearance and size of defect. This article does a brief review of the history of

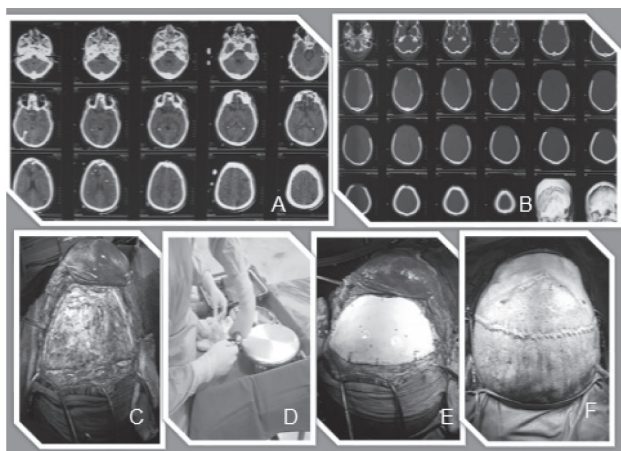


Figure 1: A) Showing the preoperative CT, B) Bi-Frontal decompressive craniectomy CT, C) Preparation of the flap, D) Mixing the bone cement, E) Completion of the BCC and fixation with non-absorbable sutures and F) closure of the wound in continuous suture

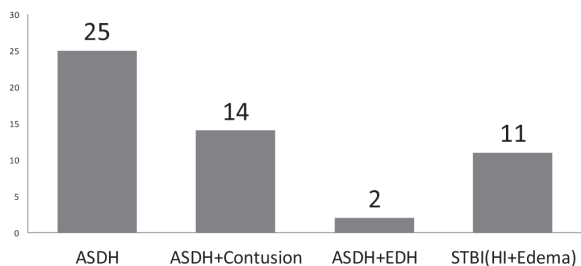


Figure 2: Showing the initial pathology in CT at admission

materials used and discusses the results of the use of bone cement cranioplasty (BCC) in this centre.

## Materials and Methods

This is a retrospective study of all cases that underwent BCC in this centre from January 2010 to February 2017. The number of cases, demographical profile, cause of injury with admission GCS, duration for cranioplasty and complications are noted.

Surgical technique consisted of early repair if possible and delayed (more than year) if infection was present. Preoperative 3-D CT was done to study the intracranial and bony defect, size, shape and any other abnormalities. The decompressive defect was opened and the flap raised. Bone cement was prepared using sterile technique and molded into the shape and size of the defect. The powder was mixed with 80 mg of Gentamycin antibiotic during preparation. The extra cement and the edges were shaped to fit the decompressive defect and ice cold water used to remove the exothermic heat during setting of the cement. Few holes were made in the centre of the mould to avoid subflap collection. 5 holes were made with drill and the cement was fixed to hole in the parent bone correspondingly to achieve an immobile cranioplasty. The skin flap was replaced and closed in two layers with the skin in continuous non-absorbable suture (Figure 1). Closed suction drain was placed for 48 hours and the sutures were removed on 14th day with follow-up at 1, 3 and 12 months.

## Results

A total of 61 cases were included in the study with the majority being males (44 cases). Road traffic accident

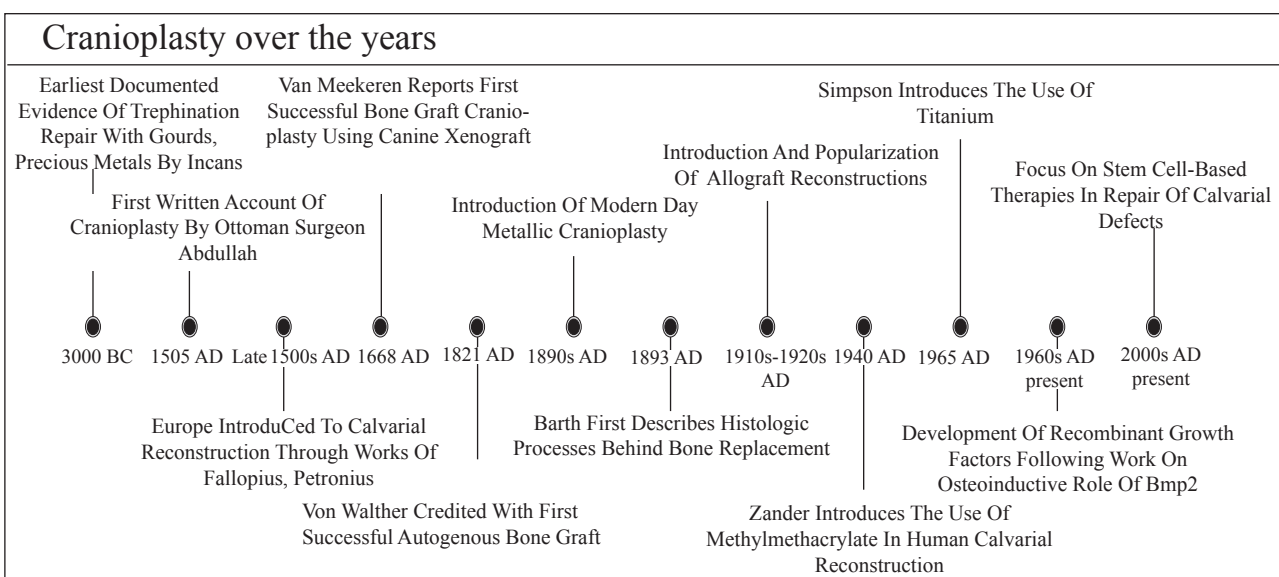


Figure 3: Timeline of the history of cranioplasty.<sup>9</sup>

## Cranioplasty

• It must fit the cranial defect and achieve complete closure
• Not dilated with heat
• Radiolucency
• Easy to shape
• Not expensive
• Resistance to infections
• Ready to use
• Strong to biomechanical processes

Table 1: Showing the characteristics of an ideal cranioplasty material 3

S. No	Complications
	Infected Flap- 5 %
	Hydrocephalus- 3 %
	Subdural Hygroma- 5 %
	Seizure- 1.6 %
	Cosmetic – 10%

Table 2: The list of complication in this study

was the most common initial cause of injury (45 cases), followed by fall (10 cases) and physical assault in the rest. On admission and based on the GCS based head injury classification the majority were in the severe head injury type (GCS<8) in 44 cases followed by moderate head injury in the rest. The initial pathology on CT showed acute subdural hematoma in the majority followed by diffuse head injury and cerebral edema (**Figure 2**). The majority of the decompressive craniectomy was done on the left side (32 cases) followed by right (22 cases) and bilateral in 7 cases (including single flap bifrontal in 5 cases). After the initial surgery the majority of the cases underwent BCC after 3 months with 15 cases undergoing within 1 month and the rest 13 cases between 1 to 3 months. There was no procedure related mortality and the morbidity was limited to infection and cosmetic complains (**Table 2**). Three cases of infection were initially tried with antibiotics and burr hole drainage of the collection failure of which needed removal of the BCC. A delayed cranioplasty was done in two cases after 12 months.

## Discussion

Decompressive craniectomy is one of the commonest emergency neurosurgical procedures performed worldwide. Non-traumatic craniectomies are also done for infection, tumours and other causes for raised intracranial pressure. These defects are managed by cranioplasty which aims not only to cover and give a cosmetic importance but also gives

a physiological and psychological relief to the patient. The earliest cranioplasties was performed by the Incas using gold, silver and gourd covers around 3000-2000 B.C. Fallopius is credited for performing the cranioplasty using a gold plate in 1523–1562 while von Meekeren was the first to utilise bone cranioplasty in 1668 (**Figure 3**).<sup>29</sup> Except for the cases with local infection, brain swelling, untreated hydrocephalus, co-morbid conditions contraindicating surgery, children less than 4 years (autograft preferred), all cases can be managed with cranioplasty. Although there is a small debate as to the timing of cranioplasty numerous studies have shown no benefit of either early or delayed surgery in non-infected cases. Those with infection can be managed at no later than 6 months after control of infection (12 months in this series).

There are numerous different techniques used to cover the cranial defect including skull reconstructions with autologous, allogenic and alloplastic substitutes. Autologous bone has been harvested from the tibia, ribs, iliac and locally from the skull. Allografts are derived from cadavers whereas Xenograft are derived from animals (bovine). There are numerous artificial materials available for cranioplasty that include Methyl methacrylate, hydroxyapatite, ceramics, and polyetheretherketone (PEEK) implants (**Table 3**). A brief description follows of the materials used with special emphasis in bone cement for cranioplasty.

### Autograft Cranioplasty

This was popularized by Ollier (1859) and Macewen (1873) with other modification in 1890 by Müller and König, the latter being the most used technique. This was superseded by the von Hacker method that utilized surrounding periosteum and outer table to cover the defect.<sup>13,22,26,40</sup> This was followed by the use of Iliac, rib, tibia, sternum and scapula for cranioplasty. Autologous bone is the most commonly used procedure to repair the defect. The initial bone, bone fragments, bone dust or local harvested bone can be fixed in situ with help of non-absorbable sutures, titanium wires or plates and even plateless fixation devices. For longer delays the bone can be safely placed inside scalp or abdominal subcutaneous flaps. Use of Cryofreezing and bone banks has led to preservation for long durations. They can also be kept in antibiotic solutions and reused with or without autoclaving. Bone flap resorption is a major problem in delayed cranioplasties which can be dealt with early surgery or replacement by synthetic grafts.

### Allograft cranioplasty

Morestin first used cadaver cartilage in 1915 because it was thought that it could resist infection although the lack of calcification was a major deterrent for further use. Cadaveric skull were also used after treatment with

Material type	Used by/ year	Advantages	Disadvantages	Present status	Reference number
<b>Autograft</b> Cranium  Tibia Rib/ Scapula  Fascia Sternum/ilium	Macewan (1885)  Exhausen Early 20 <sup>th</sup> century  -	Biocompatible, low infection, easy -do- Biocompatible  -do-, more viable Biocompatible	Limited size and shape Painful, difficult Increase complication Harvesting, mobilise Difficult, small area, inc. complications	In small defects Not used Not used  In use Not used	<b>13,22,26,40</b>
<b>Metal allografts</b> Gold/Silver  Aluminum Tantalum/lead/ Vitallium/platinum  Titanium	Incas  20 <sup>th</sup> century WW II  Recent years	Easy to mould, inert Cheap Mouldable  Easy, less infection, inert, MRI compatible	Cost, oxidation of silver  Epilepsy, infection Cost, infection, toxicity, headache  Cost	Not used  Not used Not used  In Use	<b>13,25,37,38</b>
<b>Non-Metal</b> Methyl Methacrylate  Hydroxyapatite Silicon/ Polyethylene Cortoss	WW II, Spence 1954 - 1968	Shape, any size, cheap, easy to use Less reaction Easy, mouldable, less allergy Less Infection, strong, bioactive	Infection, rejection, cosmetic Break easily Soft  Cost, limited area	In use  Limited use Not in use Limited use	<b>3,19,15,32,40</b>
<b>Allograft</b>	Early 1500	Easy to procure, cheap	Allergy, rejection, infection	Not in use	<b>8,13</b>
<b>Xenograft</b>	Early 1500	Easy to procure, cheap	Allergy, rejection, infection	Not in use	<b>8</b>
<b>ell-Based Therapies, growth factors</b>	21 <sup>st</sup> century	Reliable, osteogenic, useful in children biocompatible,	Experimental, costly, smaller size	Experimental, Small defect	<b>16,28,34,35,36,</b>

Table 3: Showing the different types of materials used and their advantages and disadvantages.

sodium carbonate, xylol, alcohol, and ether, followed by heat, for cranioplasty. This procedure though had high infection rates and was not used.<sup>8,13</sup>

#### Xenograft cranioplasty

Canine, ape, goose, rabbit, ox horn, buffalo and ivory have all been used for cranioplasties. The success of autograft and the increased complication have reduced the use of xenograft for cranioplasty.<sup>8</sup>

#### Alloplasts

#### Metals

Numerous metals have been used for cranioplasties that include Gold, Silver, lead, Aluminium (Booth and Gersten), Vitallium alloys by Geib (1941), Tantalum by Pudenz and Odom (1942); stainless steel by Boldrey, Scott, Wycis, and Murtagh (1944, 1956), titanium by

Simpson (1965) and Tantalum.<sup>10,12,13</sup> Tantalum was used during World War II but due to price, limited supply, and complications from high thermal conduction, its use was discontinued shortly.<sup>13,25,37,38</sup> The complications associated with metal implants are infection, seizure, imaging artifacts on CT scans, dislodgement, heat conduction, headache, scalp erosion or perforation, cost and lack of malleability. Titanium remains the common metal that is used today with or without bone cement. It comes in various sizes and can be shaped to fit the defect completely even in children.<sup>39</sup> Computer generated models have greatly enhanced the cosmetic and functional outcome using titanium.

#### Acrylics

Acrylic was first used in animal models which showed that it adhered to the dura with no underlying reaction. Although used primarily by dentist its use was expanded



for cranioplasty during the World War II. Acrylic is easy to shape, lighter, radiates less heat, radiolucent, cheap and easily available, giving it advantage over metals. Article of Spence in 1954 and Zander in 1940, popularized its use.<sup>15,32,40</sup> Although the choice of many for adult cranioplasty its use is limited in children and should be avoided in less than 5 years due to its lack of osteointegration.

### Methyl Methacrylate

Methyl methacrylate is a polymerized ester of acrylic acid with strength comparable to bone, strong, heat resistant, radiolucent, and inert which was discovered in 1939. The radiolucent nature could lead to angiography being done but did not show fractures for which a little amount of Barium was added. MMA comes in a powder and has to mixed with the liquid provided which forms a initial soft paste that be shaped and moulded to any size. The exothermic reaction involves use of cold water to cool down and it can be interlayered with titanium mesh. Although safe to use MMA does have few complications The exothermic reaction during preparation can lead to burn and long term complications (5-40%) include, infection (5-20%), fracture, scalp erosion or fistulization and hypersensitivity reactions(1%).<sup>5,7,17,11</sup>

### Hydroxyapatite

To counter the problems of shape and size adjustment and prevent artifacts on the CT scan Hydroxyapatite which is a hexagonal calcium phosphate compound found naturally in bone or synthetically manufactured as a ceramic was introduced. It can thus be used in children as there is little reaction and has good bonding with bone. It though has disadvantages like, low tensile strength, high infection, brittleness, disintegration with time and unpredictable response when exposed to blood or cerebrospinal fluid.<sup>14,23,33</sup> Patients with hydroxyapatite must stay away from trauma till full bone is formed.

### Alumina ceramics

These are newer materials used in cranioplasty which are hard as diamond, comparable tissue compatibility as acrylics, chemically stable, low post-operative infection and slightly radiopaque. The drawback being expensiveness, prone to shatter and need to be prefabricated before use.<sup>24,30</sup>

### PEEK Implants

Polyetheretherketone (PEEK) is a semicrystalline polymer that can be sterilized by steam or gamma irradiation. PEEK is radiolucent, chemically inert, and has strength, thickness, and elasticity comparable to cortical bone. It does not create artifact on CT or

MRI, can be shaped with computer or 3-D printing, are translucent, its porous framework allows for theoretical bony ingrowth and vascularization, non-magnetic, light with no thermal conduction. They are expensive, lack osteointegrative properties, can be dislodged and has infection problems.<sup>319,30</sup>

### Pediatric Cranioplasty

If the dura and pericranium are intact smaller defects in children close spontaneously. The basic principles of remain cranioplasty remain the same as for adults except for few limitations of the pediatric age group where the osteogenic potential of the cranium is inversely proportional and decreases rapidly after 1 year of age.<sup>31</sup> Resorption of the bone is a major problem which can be delayed with use of synthetic bone or mesh. The growing skull with its contour changes places limitations on synthetic materials and thus the results of latter are not acceptable on long term follow-up. Autologous bone remains the best choice for cranioplasty and thus must be preserved for future use. Osteogaleal flaps are an alternative for reconstruction in pediatric defects due to their membranous origin, ease of harvest, reliable vascularity, and applicability to any part of the cranium. Coralline hydroxyapatite granules mixed with Avitene and autologous blood, bone substitutes that avoid rigid fixation, osteoinductive factors such as bone morphogenetic protein (BMP) for the reconstruction, autologous cranial particulate bone grafts mixed with autologous blood are some of the other ways to achieve defect closure.<sup>6,13</sup> Before 3 years of age, the diploic space is not reliably present and the skull is thin and thus split cranial bone grafting can be performed only after 3 years and in situ cranial bone grafting only after 9 years of age. If the scalp cannot be closed primarily then preoperative subgaleal scalp expansion, skin grafting, local or pedicle vascular rotation flaps can be used for covering the defect. Some of the common flaps used include latissimus dorsi myocutaneous flap, rectus abdominus flap, radial forearm flap, and omentum flap.<sup>41</sup> The choice of a scalp cover is determined by the anatomy (size, depth, and axial blood supply) and physiology (radiation, infection) of the defect in addition to patient factors such as comorbidities, oncological issues, and cosmetic concerns.<sup>27</sup>

### The future of cranioplasty

#### Growth Factors

Histological proof that transplanted bone cells die but leave scaffolding on which living bone can form, was first described by Barth (1893). Modern research focuses on ways to improve revascularization, osteoinduction to osteoconduction and osteogenesis. Osteoinduction can lead to osteoprogenitor cells that will be produced in situ

## Roka et al

with the aid of bone morphogenetic proteins, which would be infused into an implant. Use of recombinant factors such as transforming growth factor b, insulin-like growth factor-I, and BMP-2 and tissue engineering in augmenting calvarial closure in animal and human models are being studied.<sup>16,28,36</sup>

### Stem Cell-Based Therapies

Recent advances in laboratory research have shifted the focus from osteoconduction to a more osteoinductive framework, whereby undifferentiated mesenchymal cells can be transformed into osteoprogenitor cells in situ. Stem cell-based therapies hold enormous promise in this regard, demonstrating successful repair of critical-sized cranial defects by using human induced pluripotent stem cells (iPSCs), bone marrow derived stem cells (BMSCs), and adipose-derived stem cells (ASCs) in mouse models. ASCs possess several advantages over BMSCs (possibility for malignant transformation and acquisition of foreign antigens) including rapid in vitro expansion, higher cell numbers achievable through ASC harvests and increased proliferation rates in vitro ease of harvest, and higher in vivo abundance.<sup>2,4,34,35,20,21</sup> Although iPSCs heal cranial defects concerns including teratoma formation and insertional mutagenesis persist. These concerns must be addressed and minimized prior to the use of iPSCs in clinical trials. A timeline graph is shown in **Figure 2**.<sup>9</sup>

### Present study

The present study has dealt with bone cement cranioplasty in a 7 year study. BCC is cheap, easily available, moldable and at affordable cost. This study has shown the good results associated with BCC with minimal or acceptable morbidity. Use of titanium mesh or plating could reduce the number of cosmetic side effects. The use of Gentamycin during preparation may be one reason for the reduced infection. There have been no cases with fracture and in cases of infection the redo-BCC was done at more than a year. In the cases of BCC removal even at more than 6 months there was no adhesion or neovascularization of the bone cement. Placement of a drain and smaller holes in the BCC are some ways to avoid post-operative collection.

### Conclusions

Cranioplasty for skull defects is still a challenge today in spite of all the research and improvements in materials used. Literature reported complications range from 16% to 40%, with a general reoperation rate of 25%. An ideal cranioplasty material bearing the aforementioned characteristics is yet to be available. Use of material is often dictated by the availability, cost, age of patient, personal

experience and institutional preferences. Multidisciplinary approach for complex defects is needed and hence should be done to give the best results. At present, autologous grafts, MMA, PEEK, and titanium remain the most used materials. Use of 3D printing and computer based models along with research in tissue factors will definitely change the approach to cranioplasty. In our centre as for other centres in Nepal and developing countries, bone cement remains the best, safest, cheapest choice along with autologous graft for cranioplasty.

### References

1. Asenjo A: Neurosurgical Techniques. Springfield, IL: Charles C Thomas, 1963
2. Barth A: Über histologische Befunde nach Knochenimplantationen. *Arch Klin Chir* **46**:409–417, 1893
3. Blake DP. The use of synthetics in cranioplasty: A clinical review. *Mil Med* **159**:466–9, 1994
4. Blom EJ, Klein-Nulend J, Yin L, van Waas MA, Burger EH: Transforming growth factor-β1 incorporated in calcium phosphate cement stimulates osteotransductivity in rat calvarial bone defects. *Clin Oral Implants Res* **12**:609–616, 2001
5. Blum KS, Schneider SJ, Rosenthal AD: Methyl methacrylate cranioplasty in children: long-term results. *Pediatr Neurosurg* **26**:33–35, 1997
6. Choi SH, Levy ML, McComb JG: A method of cranioplasty using coralline hydroxyapatite. *Pediatr Neurosurg* **29**:324–327, 1998
7. De Bonis P, Frassanito P, Mangiola A, Nucci CG, Anile C, Pompucci A: Cranial repair: how complicated is filling a “hole”? *J Neurotrauma* **29**:1071–1076, 2012
8. Durand JL, Renier D, Marchac D: The history of cranioplasty. *Ann Chir Plast Esthet* **42**:75–83, 1997 (Fr)
9. Feroze AH, Walmsley GG, Choudhri O, Lorenz HP, Grant GA, Edwards MS. Evolution of cranioplasty techniques in neurosurgery: historical review, pediatric considerations, and current trends. *J Neurosurg* **123**:1098-107,2015
10. Gardner WJ: The use of tantalum for repair of cranial defects in infected cases. *Cleve Clin Q* **13**:72–87, 1946
11. Gautschi OP, Schlett CL, Fournier JY, Cadosch D: Laboratory confirmed polymethyl-methacrylate (Palacos)-hypersensitivity after cranioplasty. *Clin Neurol Neurosurg* **112**:915–916, 2010
12. Geib FW: Vitallium skull plates. *JAMA* **117**:8–12, 1941

13. Grant FC, Norcross NC: Repair of cranial defects by cranioplasty. **Ann Surg** **110**:488–512, 1939
14. Grant GA, Jolley M, Ellenbogen RG, Roberts TS, Gruss JR, Loeser JD: Failure of autologous bone-assisted cranioplasty following decompressive craniectomy in children and adolescents. **J Neurosurg** **100 (2 Suppl Pediatrics)**:163–168, 2004
15. Gurdjian ES, Webster JE, Brown JC: Impression technique for reconstruction of large skull defects. **Surgery** **14**:876–881, 1943
16. Hock JM, Centrella M, Canalis E: Insulin-like growth factor I has independent effects on bone matrix formation and cell replication. **Endocrinology** **122**:254–260, 1988
17. Jaber J, Gambrell K, Tiwana P, Madden C, Finn R: Longterm clinical outcome analysis of poly-methyl-methacrylate cranioplasty for large skull defects. **J Oral Maxillofac Surg** **71**:e81–e88, 2013
18. Khader BA, Towler MR. Materials and techniques used in cranioplasty fixation: A review. **Mater Sci Eng C Mater Biol Appl** **66**:315-22, 2016
19. Lethaus B, Safi Y, ter Laak-Poort M, Kloss-Brandstätter A, Banki F, Robbenmenke C, et al: Cranioplasty with customized titanium and PEEK implants in a mechanical stress model. **J Neurotrauma** **29**:1077–1083, 2012
20. Levi B, Hyun JS, Montoro DT, Lo DD, Chan CK, Hu S, et al: In vivo directed differentiation of pluripotent stem cells for skeletal regeneration. **Proc Natl Acad Sci U S A** **109**:20379–20384, 2012
21. Levi B, James AW, Nelson ER, Vistnes D, Wu B, Lee M, et al: Human adipose derived stromal cells heal critical size mouse calvarial defects. **PLoS ONE** **5**:e11177, 2010
22. Macewen W: An address on the surgery of the brain and spinal cord. **Br Med J** **2**:302–309, 1888
23. Martini L, Staffa G, Giavaresi G, Salamanna F, Parrilli A, Serchi E, et al: Long-term results following cranial hydroxyapatite prosthesis implantation in a large skull defect model. **Plast Reconstr Surg** **129**:625e–635e, 2012
24. Matsuno A, Tanaka H, Iwamuro H, Takanashi S, Miyawaki S, Nakashima M, et al: Analyses of the factors influencing bone graft infection after delayed cranioplasty. **Acta Neurochir (Wien)** **148**:535–540, 2006
25. Mayfield FH, Levitch LA: Repair of cranial defects with tantalum. **Am J Surg** **67**:319–332, 1945
26. Müller P: Deckung von schädeldefekten aus dem sternum. **Zentralbl Chir** **23**:409–410, 1915
27. Mulliken JB, Glowacki J, Kaban LB, Folkman J, Murray JE: Use of demineralized allogeneic bone implants for the correction of maxillocraniofacial deformities. **Ann Surg** **194**:366–372, 1981
28. Reddi AH: Morphogenesis and tissue engineering of bone and cartilage: inductive signals, stem cells, and biomimetic biomaterials. **Tissue Eng** **6**:351–359, 2000
29. Sanan A, Haines SJ: Repairing holes in the head: a history of cranioplasty. **Neurosurgery** **40**:588–603, 1997
30. Shah AM, Jung H, Skirboll S. Materials used in cranioplasty: a history and analysis. **Neurosurg Focus** **36**:E19,2014
31. Shonka DC Jr, Potash AE, Jameson MJ, Funk GF: Successful reconstruction of scalp and skull defects: lessons learned from a large series. **Laryngoscope** **121**:2305–2312, 2011
32. Spence WT: Form-fitting plastic cranioplasty. **J Neurosurg** **11**:219–225, 1954
33. Teixeira S, Fernandes H, Leusink A, van Blitterswijk C, Ferraz MP, Monteiro FJ, et al: In vivo evaluation of highly macroporous ceramic scaffolds for bone tissue engineering. **J Biomed Mater Res A** **93**:567–575, 2010
34. Thesleff T, Lehtimäki K, Niskakangas T, Mannerström B, Miettinen S, Suuronen R, et al: Cranioplasty with adiposederived stem cells and biomaterial: a novel method for cranial reconstruction. **Neurosurgery** **68**:1535–1540, 2011
35. Urist MR: Bone: formation by autoinduction. **Science** **150**: 893–899, 1965
36. Verheggen R, Merten HA: Correction of skull defects using hydroxyapatite cement (HAC)—evidence derived from animal experiments and clinical experience. **Acta Neurochir (Wien)** **143**:919–926, 2001
37. White JC: Late complications following cranioplasty with alloplastic plates. **Ann Surg** **128**:743–754, 1948
38. Wollaston WH: On the identity of columbium and tantalum. **Philos Trans R Soc Lond** **99**:246–252, 1809
39. Woodhall B, Spurling RG: Tantalum cranioplasty for war wounds of the skull. **Ann Surg** **121**:649–668, 1945
40. Woolf JI, Walker AE: Cranioplasty: collective review. **Int Abstr Surg** **81**:1–23, 1945
41. Yamada H, Sakai N, Takada M, Ando T, Kagawa Y: Cranioplasty utilizing a preserved autogenous bone flapcoated with acrylic resin. **Acta Neurochir (Wien)** **52**:273–280, 1980