

Case Report

Prabin Shrestha, MD, PhD
Department of neurosurgery
Norvic International Hospital
Thapathali, Kathmandu

Anish M Singh, MS
Department of neurosurgery
Norvic International Hospital
Thapathali, Kathmandu

Hemant Sah, MS
Department of neurosurgery
Norvic International Hospital
Thapathali, Kathmandu

Bidur Baral MD
Department of Anesthesiology
Norvic International Hospital
Thapathali, Kathmandu

Address for correspondence:
Dr Prabin Shrestha, MD, PhD
Department of neurosurgery
Norvic International Hospital
Thapathali, Kathmandu
Email: prabinshrestha@hotmail.com

Received. 3 April, 2015
Accepted, 21 April, 2015

Successful clipping of A Giant Basilar Tip Aneurysm: A Case Report with Review of literature

Basilar tip aneurysm is the commonest aneurysm in posterior circulation. It comprises of about 5% of total aneurysms of cerebral circulation. Giant basilar tip aneurysm is rare and is technically challenging. Bigger is the aneurysm more complex is its structure leading to technical difficulty in its treatment, may it be surgical clipping or endovascular coiling.

We present 50-year-old male patient presented with sudden and severe headache with altered consciousness. CT head showed sub arachnoid hemorrhage and CT angiography showed giant basilar tip aneurysm measuring more than 23 mm in length. Moreover basilar tip bifurcation and both the posterior cerebral artery arose from posterior aspect of lower part of the trunk of aneurysm. Because of the huge size and origin of the major branches from aneurysm trunk surgical clipping seemed highly risky. Patient was planned for coil embolization in India. But due to cost factor surgical clipping was planned.

Successful clipping was done through right frontotemporal transtentorial approach. Small residual aneurysm was noted in the anterior lower part of aneurysm trunk which was wrapped with hemostatic agents. Complete resection of the aneurysm was done showing complete obliteration of the aneurysm. Post operatively patient was neurologically intact except ipsilateral oculomotor nerve palsy.

Patient was discharged on 6th post operative day.

Nepal still lacks endovascular coiling facility. Cost factor is a major hindrance for this. Surgical clipping is still the first choice of treatment for any aneurysm in Nepal. There is no alternative to skill development and successful clipping for treating aneurysm in Nepal.

Key Words: cerebral aneurysm, clipping, giant basilar tip aneurysm

Intracranial aneurysms are more common in anterior circulation of cerebral vessels. They are also found in posterior circulation but less commonly. Basilar tip is more commonly involved in aneurysm formation in posterior circulation. Large aneurysms are less commonly found. Giant aneurysms are even rare.^{4,9}

Basilar tip aneurysm is still a challenge due to difficult

anatomy of aneurysm, difficult approach, presence of arterial branches and small perforators. Proximity to brain stem and possibility of brain stem infarction due to involvement of perforators while clipping make the surgery extremely highly risky. It is more so in case of giant aneurysm. Here we present a case of giant basilar tip aneurysm with very high risk of surgical clipping.

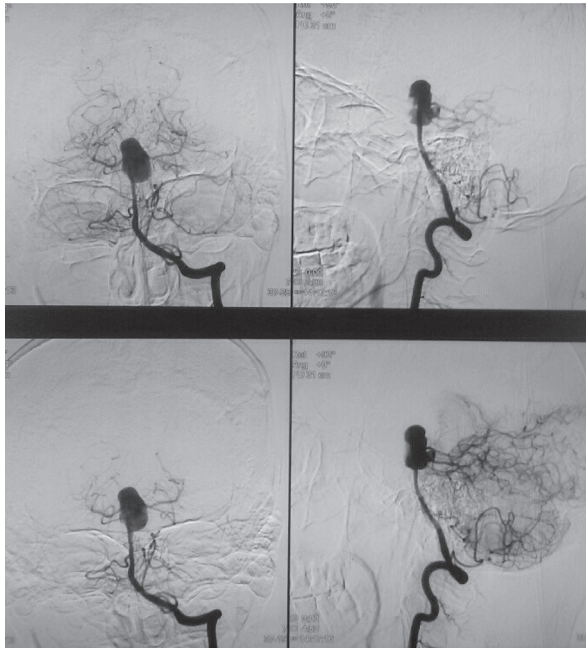


Figure 1: Cerebral angiography (DSA) showing giant basilar tip aneurysm

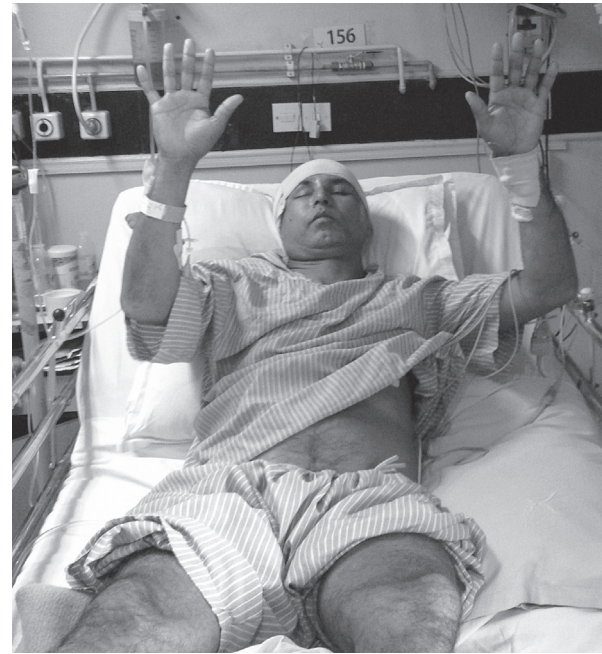

Figure 2: Two days after surgery showing normal neurological status

Case report

A 50-year-old male came from Jhapa, Nepal with sudden loss of consciousness 6 days ago. He was primarily treated there and was slowly getting better. The patient was referred to India from there, however patient came to Kathmandu for further treatment. Patient party came to the first author of this article and discussed about the case. Patient was thus brought to Norvic hospital where conservative treatment was continued for few days and was further evaluated with CT angiography (CTA) of cerebral vessels and conventional digital subtraction cerebral angiography (DSA) (**Figure 1**). The condition of patient improved slowly and became fully conscious. He was neurologically stable.

CTA and DSA showed high lying giant cerebral aneurysm measuring about 25 mm lying on Basilar top. Both the P1 segments of posterior cerebral arteries (PCA) were found to be arising from the lower portion of posterior dome. Since the aneurysm seemed to be technically difficult and highly risky for clipping in Nepal, patient was suggested to go to India for coiling. Discussion with Indian neurosurgeons in Delhi, India revealed the total cost of about twenty five lakh Nepalese Rupees. They also informed that the coiling of aneurysm was also going to be highly risky due to its size and vessels arising from it. After hearing from Delhi, patient party refused to go to India and instead insisted for treatment in Nepal.

After getting informed consent, surgery was planned on 14th day of initial bleed.

Surgical Procedure

Right fronto temporal transtentorial approach was selected. Head was fixed on 3 pin Mayfield head holder and rotated about 15° towards left. Neck was slightly flexed.

Incision was given in right pterional area and frontotemporal craniotomy was done. Right optic nerve and internal carotid artery (ICA) were exposed and fluid (CSF) was drained. Part of aneurysm was immediately seen after slight dissection of right carotid oculomotor space. Part of aneurysm dome was also reached from pre-chiasmatic cistern. However neck of aneurysm and surrounding vessels were note clearly visible.

It was very difficult to find the basilar artery (BA) due to huge size of aneurysm. Therefore free edge of tentorium was cut to expose the basilar artery. Care was taken not to injure the oculomotor nerve. Hypoplastic posterior communicating artery (PComA) was identified which was hindering the approach to the aneurysm. Therefore PComA was coagulated and divided. With further dissection proximal neck and dome along with origin of both P1s were identified. BA was also well exposed and temporary clip was applied on it. The aneurysm was coagulated with low voltage bipolar coagulator so that entire aneurysm could be seen. With further dissection, long straight clip was applied just distal to the origin of both P1s. temporary clip was removed. Clip seemed to be slightly pressing the origins of P1s. Remanipulation of the clip was done to place it slightly above the origin of P1s. Intact P1s were

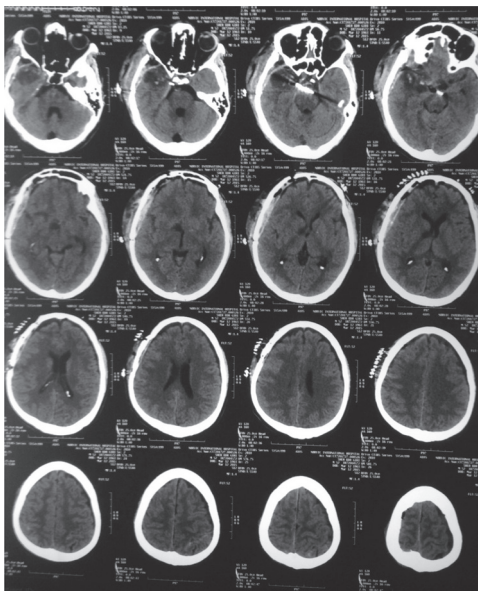


Figure 3: Post operative CT scan showing post operative changes and clip in situ

confirmed by the pulsation of both the PCAs. Aspiration of the aneurysm dome was done by 1 ml syringe. No actively gushing out of blood was noted. Further coagulation of aneurysm was done and shrinkage of the total aneurysm was noted. Complete exposure of the aneurysm from all around was obtained. Total resection of aneurysm was done which showed complete occlusion of aneurysm by the clip. Residual part of aneurysm in inferoposterior area was wrapped with fibers of haemostatic agents. All the nearby perforators were secured.

Lamina terminalis was then opened and CSF was drained to prevent possible future hydrocephalus.

Postoperatively patient was placed in ventilator for whole night with sedation but without paralyzing agents. Patient was extubated next day and liquid was allowed to drink. Ipsilateral oculomotor palsy was noted, otherwise there was no neurological deficit (**Figure 2**).

Normal diet was allowed after 2 days and he was discharged from hospital on 6th days of surgery. Post operative CT scan was normal without any ischemic change (**Figure 3**).

Right third nerve palsy completely recovered after 3 months.

Discussion

Clipping and coiling are the two main modes of treatment of any aneurysm. With advanced techniques and technologies, coiling has become the procedure of choice in many types of aneurysm while clipping is still a preferred procedure in certain types of aneurysms. Tateshima et al explained their experience of treating

basilar tip aneurysms with coiling.¹⁰ They showed it an effective treatment for majority of basilar tip aneurysms. Klein et al have the same experience with coiling of basilar tip aneurysm.⁶

However, for giant basilar tip aneurysm, possibility of incomplete coiling and intra-operative rupture were high, thus clipping is still regarded a better option. Moreover, in the developing countries like Nepal where medical technology is still lagging far behind, coiling is limited to theoretical knowledge.⁵

Huntarian ligation is one of the procedures for treating giant basilar tip aneurysm. By this the blood flow diversion to the aneurysm is obtained and later the aneurysm can be completely clipped or coiled.⁸ However, there can be adverse effect in particular cases, thus it can't be applied for all the cases.

Bypass surgery is a better option for complex and giant basilar tip aneurysm. Clipping of aneurysm or ligation of proximal BA along with by pass to PCA is the best way to treat giant basilar tip aneurysm where possibility of need of sacrificing PCA is very high.^{2,7}

Cardiac standstill or asystole is another option to deal with giant basilar tip aneurysm. It reduces blood flow to the aneurysm thus reducing its tension. Similarly reduced cerebral blood flow will make the brain more relaxed and facilitate dissection around the aneurysm. This will greatly ease the aneurysm clipping.³ However this is technically highly demanding and thus not practical in the context of countries like Nepal.

Regarding open surgery for basilar tip aneurysm, different approaches have been described. Though most common approach is pterional or subtemporal approach, different skull base approaches have also been explained.¹ A cranio-orbital-zygomatic approach was used for the acute stage of a ruptured basilar tip artery aneurysm and for a giant posterior cerebral artery aneurysm. This approach provides a wide field and excellent exposure of vital structures with minimal brain retraction and thus successful neck clipping of the aneurysms was achieved.

Having explained so many different methods and approaches for treating giant basilar tip aneurysms, the only possible treatment in Nepal so far was open surgery without cardiac standstill and without bypass surgery due to technical limitation. Thus we adopted usual pterional craniotomy with transylvian approach to the aneurysm thus successfully clipping the giant aneurysm.

Conclusion

Despite having technical limitation, careful surgery with adequate previous experience and skill development can cure even difficult cases.