

## Case Report

**Dinesh K Thapa, MBBS**

Annapurna Neurological Institute and Allied Sciences  
Kathmandu, Nepal

**Chandra P Limbu, MBBS MS**

Annapurna Neurological Institute and Allied Sciences  
Kathmandu, Nepal

**Ajit Gurung MBBS, MD**

Annapurna Neurological Institute and Allied Sciences  
Kathmandu, Nepal

**Basant Pant, MD, PhD**

Annapurna Neurological Institute and Allied Sciences  
Kathmandu, Nepal

### Address for correspondence:

Dinesh K Thapa, MBBS  
Annapurna Neurological Institute and Allied Sciences  
Kathmandu, Nepal

**Email:** dineshkhthapa@gmail.com

**Received,** 2 June, 2016

**Accepted,** 14 June, 2016

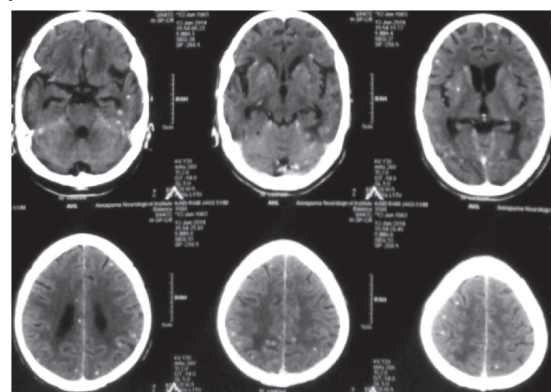
# Neurocysticercosis Presented with Acute Psychosis: A Case Report

Neurocysticercosis is the parasitic disease caused by ingestion of egg of *Tinae Solium*. The disease presents with spectrum of clinical manifestations like seizure, headache, neurological deficit and psychiatric symptoms such as psychosis. Even though most commonly patients of neurocysticercosis present with seizure, rarely, it may produce symptoms of neuropsychiatric disorder such as psychosis. Here, we are going to report a case of a patient who presented with features of acute psychosis. Later on with diagnostic imaging like CT and MRI, he was diagnosed as a case of multiple neurocysticercosis. He was then managed with anti psychotics, AEDs, Anti-helminthic drugs and steroids.

**Key Words:** Albendazole, cysticercosis, neurocysticercosis, psychosis, *Taenia solium*

**N**eurocysticercosis (NCC) is the most common parasitic disease of the brain caused by accidental ingestion of eggs of *Tinae Solium*. Specially in developing nations like Nepal, the burden of neurocysticercosis is high due to poor sanitation and low socio-economic status. Computerized tomography scan (CT-scan) and Magnetic Resonance Imaging (MRI) techniques are most commonly used tools of investigation, which often show the lesion as ring enhancing cyst in the brain.<sup>9,4</sup> Other serological tests such as Enzyme linked immunosorbent assay (ELISA) and/or Enzyme linked immunoelectrotransfer blot (EITB) further help to confirm diagnosis.<sup>3,7</sup> Seizure is the most common presentation of the disease but it may present with features of raised ICP such as headache or even neuropsychiatric disorders such as psychosis.<sup>2,5,8</sup> Here, we are going to report a case of

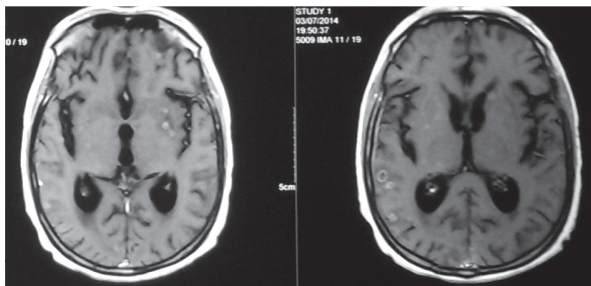
neurocysticercosis, who presented with features of acute psychosis.



*Figure 1: CT Contrast showing calcified and ring enhancing lesions*

## Case Report

A 51-year-old male presented to emergency department with complaint of abnormal behavior, irrelevant talk, irritability, episodes of anger, poor eye contact and continuous speech at increased rate, rhythm and intensity. Initially the patient was treated with inj. Midazolam followed by Inj. Lorazepam. Once the patient was sedated and calm, his CT brain (both plain and enhanced) was obtained which revealed multiple calcified lesions suggestive of NCC (**Figure 1**). The patient was admitted in Intermediate Care Ward (ICW) for close monitoring and treatment. His other blood investigations were sent which were normal. The patient's MRI brain was obtained which also revealed neurocysticercosis of different stages as shown in **Figure 2**. The EITB (Emzyme-Linked Immunotransfer blot) test was done which was positive, confirming the diagnosis.



*Figure 2: MRI Brain showing multiple ring enhancing lesions, suggestive of neurocysticercosis*

He was treated with oral anti-psychotic medications and intravenous sedation whenever needed. Intra-ocular cyst was ruled out after evaluation by an ophthalmologist. The multiple Neurocysticercosis was then treated with steroids and Albendazole (400mg twice a day, advised for 4 weeks). During his stay, he had 1 episode of Generalized Tonic Clonic Seizure (GTCS), for which Sodium Valporate was started. After few days of stay, patient recovered completely and therefore discharged with oral antipsychotic and antiepileptic medications.

## Discussion

Neurocysticercosis is caused by the cyst, which is the larval stage of pork tapeworm called *Tinea Solium*. It enters the central nervous system by ingestion of its eggs from contaminated hand, water or food.<sup>9</sup> In developing countries like Nepal, neurocysticercosis is the most common parasitic disease of the central nervous system and is also the main cause of acquired epilepsy. The disease is endemic in countries with poor sanitation; however it is increasingly being reported in developed countries as well due to globalization and immigration.

Neurocysticercosis is a pleomorphic disease. Epilepsy is the most common presentation (70%) of neurocysticercosis and is also a complication of the disease.<sup>9</sup> A myriad of papers have reported a wide range of diverse symptoms and signs related to NCC, such as manifestations of brainstem dysfunction, cerebellar ataxia, sensory deficits, involuntary movements, stroke-like symptoms, extra-pyramidal signs, dementia, Bruns syndrome, Kluver-Bucy syndrome, cortical blindness, etc.<sup>4</sup> Pharmaceutical treatments for cysticercosis are most commonly albendazole and praziquantel. Albendazole (15 mg/kg per day ~ 800 mg/day in two divided doses) facilitates the destruction of parenchymal cysticerci. Praziquantel (50 to 100 mg/kg per day in three divided doses) is an alternative to albendazole; these drugs are also used to treat intestinal taeniasis.<sup>3</sup> Among the multiple psychiatric manifestations of neurocysticercosis, psychosis may be seen in up to 5% of patients.<sup>8</sup> In a series of studies conducted in Brazil, psychiatric disorders occurred in 65.8%, evidence of cognitive decline in 87.5%, depression in 52.6%, and psychosis in 14.2% of patients.<sup>5</sup> Involvement of the subarachnoid space may lead to the visual and hormonal impairment by direct compression of the hypophyseal stem and the optic nerves; which is reported in 3.5% of the patients.<sup>10</sup> The neuropsychiatric symptoms of NCC can be attributed to mechanical alterations in CSF pressure and inflammatory injury of the brain.<sup>1</sup> In Nepal, Joshi DD, et al in 2006 found that prevalence of NCC ranges from 0.002 to 0.1%, and studies on porcine cysticercosis seem to be rather high, e.g., the prevalence was 32.5% in 419 individual porcine samples tested by lingual palpation technique.<sup>6</sup> Another study conducted in a Kathmandu Model Hospital by Pant B et al in 2006 showed the mean age was 13 years, both sexes were found equally affected, 71% showed stage II lesions (dying cyst with or without edema, and the remaining patients had stage III lesions (calcified). Overall, 61% of lesions were solitary and 31% were multiple lesions (n=724 patients).<sup>2</sup>

## Conclusion

Although seizure is the most common presentation of neurocysticercosis, it may manifest with varieties of symptoms. One such rare presentation is acute psychosis. Therefore, clinicians should bear in mind that the underlying organic cause for acute psychosis may be neurocysticercosis, especially in a country like Nepal where its prevalence is relatively high.

Hence, neurocysticercosis should be kept in the differential diagnosis if a patient presents with psychosis.

## References

1. Nash TE, Garcia HH. Diagnosis and treatment of neurocysticercosis. **Nat Rev Neurol** 7:584-594, 2011
2. Del Brutto OH, Santibanez R, Noboa CA, Aguirre R, Diaz E, Alarcon TA. Epilepsy due to neurocysticercosis: analysis of 203 patients. **Neurology** 42:389-392, 1992
3. Carpio A. Neurocysticercosis: an update. **Lancet Infectious Diseases** 2:751-762, 2002
4. Levenson JA. Textbook of Psychosomatic Medicine. Washington, DC: American Psychiatric Publishing, 2005
5. Mahajan SK, Machhan PC, Sood BR, et al. Neurocysticercosis presenting with psychosis. **J Assoc Physicians India** 52:663-665, 2004
6. Forlenza OV, Filho AH, Nobrega JP, et al. Psychiatric manifestations of neuro-cysticercosis: A study of 38 patients from a neurology clinic in Brazil. **J Neurol Neurosurg Psychiatry** 62:612-616, 1997
7. S Sinha, B S Sharma. Neurocysticercosis: A Review of Current Status and Management. **Journal of Clinical Neuroscience** 16:867-876, 2009
8. A Biswas, A Prasad, KS Anand. Cysticercal Dementia. **Journal of Association of Physicians of India** 46:569, 1998
9. Joshi DD, Bista PR, Ito A, Yamasaki H: Present situation of porcine taeniasis and human cysticercosis in Nepal. **South East Asian Journal of Tropical Medicine and Public Health** 38:144, 2007
10. Bishnu Joshi, Basant Pant et al: The Epidemiology and Health Burden of Neurocysticercosis in Nepal. **International Journal of TROPICAL DISEASE & Health** 4: 204-223, 2014