

A Case of Large Benign Bifrontal Cyst

Yam B Roka, MS, MCh

Department of Neurosurgery
Neuro Cardio and Multispecialty Hospital
Biratnagar-13, Nepal

Alok Jha, MBBS

Department of Neurosurgery
Neuro Cardio and Multispecialty Hospital
Biratnagar-13, Nepal

Address for correspondence:

Yam B Roka, MS, MCh
Chief of Neurosurgery
Neuro Cardio and Multispecialty Hospital
Jahada Road, Biratnagar-13, Nepal
Email: dryamroka@yahoo.com

Received, 15 February, 2016

Accepted, 3 March, 2016

A 16-month-old male presented with progressively enlarging head for 12 months, decreased appetite and drowsiness for 1 month and downgazing eye for 15 days. There was no history of fever, vomiting, seizure or any antenatal issues. On examination the child was not obeying command and had a weak cry with no obvious motor deficit. A computed tomogram (CT) was done which showed a large bifrontalmultiseptate lesion with minimal hydrocephalus displacing the frontal lobes and extending across midline (**Figure 1 A**). A low pressure cyto-peritoneal was inserted with clinical improvement next day. The fluid analysis was negative for infection and malignancy. The child was discharged home on the seventh day and is asymptomatic for the past one year (**Figure 1 B**). Repeat scan at 1 year showed complete collapse of the cyst (**Figure 1 C**).

Intracranial cyst in children is uncommon findings in neurosurgery. These can be found in different brain compartments and may have diverse origins. Of these choroid plexus and arachnoid cysts are the most common and usually have a good prognosis.¹ Among the intraparenchymal cysts, the periventricular pseudocysts, ependymal cyst, neuroepithelial; cyst, cystic periventricular leukomalacia, and the porencephalic cystic lesions are the most representative.^{2,3} Other uncommon causes are

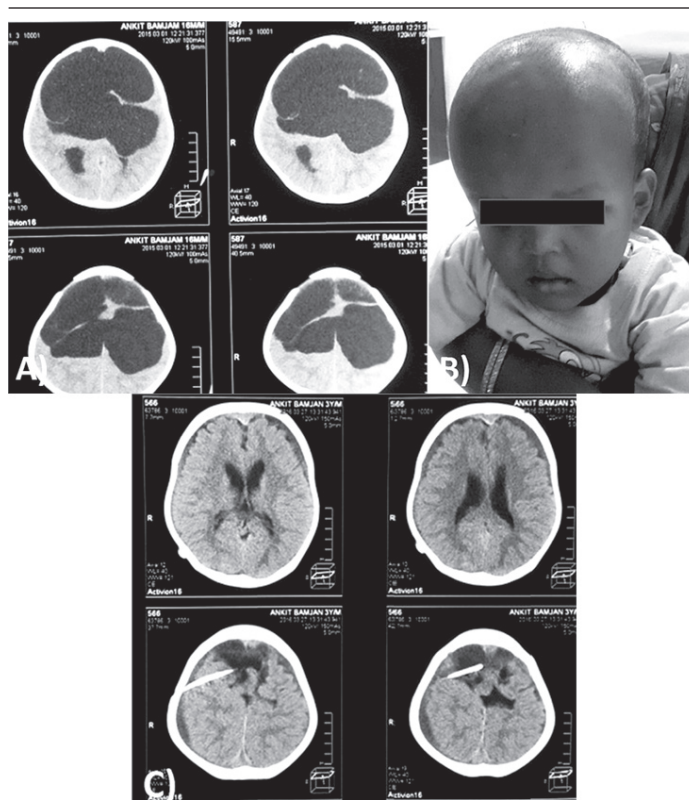


Figure 1: A) Showing a large Intracranial multiseptate bifrontal cyst, B) Showing a healthy child at one year, C) Showing cysto-peritoneal shunting at one year

hydatid cyst, intracerebral abscess, cyst with glioma and trapped lateral ventricle. The prognosis depends on the presence of associated findings and on the extent and place of the insult. The diagnosis is with CT or a Magnetic Resonance imaging. Management consist of serial follow-up if small and asymptomatic to surgery which includes fenestration- endoscopic or open, shunting of contents, complete excision or marsupialisation.

References

1. Osborn AG1, Preece MT. Intracranial cysts: radiologic-pathologic correlation and imaging approach. **Radiology** 239:650-664, 2006
2. Pappalardo EM1, Militello M, Rapisarda G, et al. Fetal intracranial cysts: prenatal diagnosis and outcome. **J Prenat Med** 3:28-30, 2009
3. Preece MT1, Osborn AG, Chin SS, Smirniotopoulos JG. Intracranial neurenteric cysts: imaging and pathology spectrum. **Am J Neuroradiol** 27:1211-1216, 2006