

Original Article**Shyam C Meena, MD**Department of Anaesthesiology & Intensive Care
Government Medical College
Kota, Rajasthan, India**Suresh C Dulara, MD**Department of Anaesthesiology & Intensive Care
Government Medical College
Kota, Rajasthan, India**Sachidanand Gautam, MS, MCh**Department of Neurosurgery
Government Medical College
Kota, Rajasthan, India**Sharad Beldar, MD**Department of Anaesthesiology & Intensive Care
Government Medical College
Kota, Rajasthan, India**Address for correspondence:**Shyam C Meena, MD
Department of Anaesthesiology & Intensive Care,
Government Medical College,
Kota, Rajasthan, India
Email: drshyam.pgi@gmail.com**Received,** 9 April, 2016**Accepted,** 23 April, 2016

Peri-operative Considerations in Intracranial Hemorrhage in Dengue Virus Infected Patients: A Prospective Mini Case Series

Dengue is one of the most common mosquito-transmitted arboviral diseases of tropical and few subtropical areas of the world. It is estimated that 100 million cases occur every year and 2.5 billion people are at risk. Hemorrhagic complications causing encephalopathy is quite a rare presentation but usually fatal. We discuss the peri-operative management of 8 uncommon cases of intracranial hemorrhage (ICH) in dengue. High index of suspicion is required for prompt diagnosis and treatment.

Eighteen dengue serology positive patients who presented with neurological manifestations were managed in neurosurgery unit of our tertiary health care center in six months duration. Most of the patients had deranged prothrombin time and thrombocytopenia. They were given platelet concentrates for correction of thrombocytopenia. All vital parameters and neurologic status were closely monitored in high dependency unit. Eight of these patients had deterioration in neurologic status; five of them underwent surgery.

All patients who underwent surgery had excellent outcome. Rest of the patients including one patient of cervical extradural hemorrhage were managed conservatively with intravenous fluid and cerebral decongestants. Two patients with deep-seated bleed deteriorated very rapidly and died. Rest who were managed either surgically or conservatively including cervical EDH improved well without any residual deficit.

High index of suspicion of ICH is required in dengue especially during convalescence. Special attention should be given to those patients who are disoriented and have altered sensorium and should not be misinterpreted as fever delirium or toxic encephalopathy. It needs immediate attention and investigation. Timely diagnosis and intervention can save lives.

Key Words: Dengue hemorrhagic fever, dengue hemorrhagic shock syndrome, encephalopathy, subdural hematoma

Dengue is a mosquito-borne infection transmitted to humans by *Aedes aegypti* and caused by one of the four closely related virus serotypes of the genus *Flavivirus*, family *Flaviviridae*. The global prevalence of dengue has grown dramatically in recent

decades. It is endemic in different parts of the world. Dengue fever and dengue hemorrhagic fever (DHF) are acute febrile diseases found in the tropics with a geographic distribution similar to malaria.¹¹ Encephalopathy is quite rare but fatal complication of dengue virus infection. The

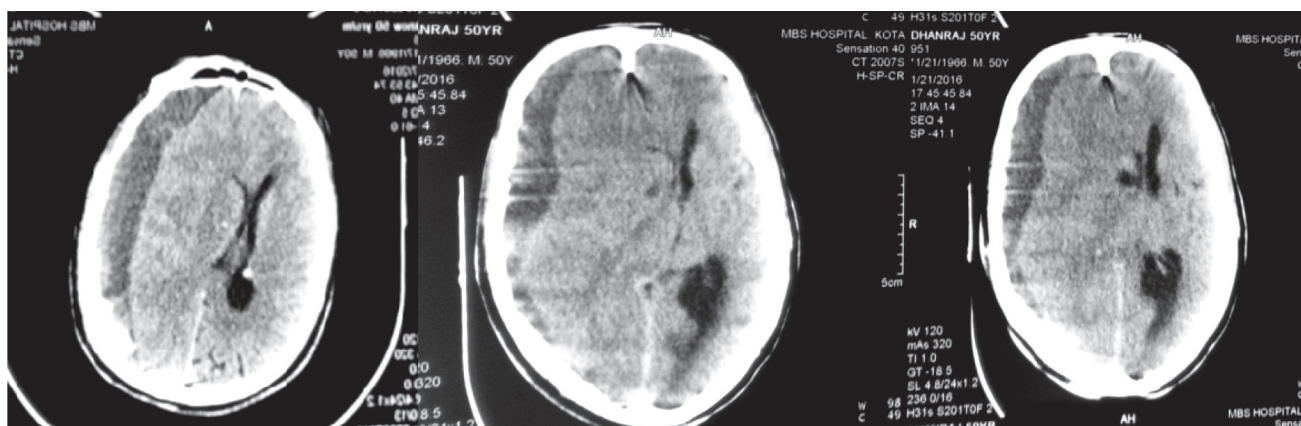


Figure 1: Extra-axial hypodense concavo-convex subdural collection seen in fronto-parietal region causing effacement of adjacent sulci and compressive effect over ipsilateral lateral ventricle along with midline shift towards contralateral side.

treatment of DHF with CNS involvement is supportive and symptomatic and rarely needs surgical intervention.¹³ We report this uncommon complication of dengue in 8 dengue patients who presented with brain hemorrhage out of total eighteen dengue serology positive patients with neurological symptoms admitted in a single hospital and discuss their management and outcome.

Materials and Methods

We present a mini-series of 8 cases of DHF with intracranial hemorrhage (ICH) admitted at government medical college and attached hospitals, Kota, Rajasthan.

We made a few interesting observations in our series (Figure 1). All these patients were perfectly healthy without any predisposing factor for intracranial bleed

like head injury, hypertension or previously known coagulopathy before this episode of illness (Table 1).

All these seropositive cases were young adults, had typical clinical presentations, prolonged PT, and severe thrombocytopenia. They developed ICH around convalescence (1 week after the onset of fever). All of them had moderate to severe headache before neurologic deterioration. Only few of them had history of nasal bleed and petechiae. All the patients were given platelet concentrate transfusions to keep platelet count above 100000/mL and blood components were made available during peri-operative period. Adequate hydration was maintained peri-operatively and cerebral decongestants were used as per neurosurgeons' instructions. Scalp block with dexmedetomidine infusion was used in two patients for chronic subdural hemorrhage surgery while

SN	Age/Sex	Serology	Blood investigations	Clinical presentation	Surgical diagnosis	Management	Anesthesia	Clinical outcome
1.	37/M	Type-2	Thrombocytopenia	Poor GCS	EDH	Craniotomy & hematoma evacuation	GA	Discharged
2.	50/M	Type-2	Thrombocytopenia	Poor GCS	EDH	Craniotomy & hematoma evacuation	GA	Discharged
3.	25/M	Type-2	Thrombocytopenia	Poor GCS	SDH	Craniotomy & hematoma evacuation	GA	Discharged
4.	50/M	Type-2	Thrombocytopenia	Poor GCS	Chronic SDH	Burr hole & hematoma evacuation	Scalp block with sedation	Discharged
5.	28/F	Type-2	Thrombocytopenia	Poor GCS	Brain stem bleed	Conservative		Died
6.	44/M	Type-2	Thrombocytopenia	Altered sensorium	Chronic SDH	Burr hole & hematoma evacuation	Scalp block with sedation	Discharged
7.	41/M	Type-2	Thrombocytopenia	Very poor GCS	ICH	Conservative		Died
8.	37/F	Type-2	Thrombocytopenia	Paresthesia	Cervical EDH	Conservative		Discharged

Table1: Demographic details of the enrolled dengue infected patients with neurological manifestations.

Intracerebral Hemorrhage in Dengue

the rest were managed with balanced general anesthetic with mechanical ventilation. Short acting anesthetic drugs were used and general anesthesia was maintained with oxygen, isoflurane and vecuronium. All operated patients were extubated immediately in post-operative period and shifted to neurosurgery ICU.

Discussion

Dengue is a mosquito-borne infection caused by arbovirus. This disease is caused by any one of the 4 different strains of the virus⁶, dengue 1, 2, 3, and 4. People can be infected by one or more types during one episode of illness but only once by the same type in lifetime. Dengue 1 causes high fever and joint pains, dengue 2 causes hemorrhagic fever resulting in spontaneous bleeding from skin and gums. Dengue 3 causes high fever, while dengue 4 causes DHF with shock. Each serotype is different from the other and there is no cross-protection. Epidemics can be caused by multiple serotypes.⁸

It is estimated that every year there are 100 million cases of dengue fever and 2.5 billion people are at risk. Dengue is the second most important mosquito-borne disease affecting humans after malaria.¹¹ Dengue fever is endemic in some parts of India.³ Incidence of dengue increases following monsoon (rainy season) when the conditions are ideal for mosquito breeding - hot and humid environment with water pooling. Primary prevention of dengue mainly resides in eliminating or reducing the mosquito vector for dengue.⁷

The diagnosis of dengue is usually clinical. According to WHO definition⁴, dengue hemorrhagic fever is diagnosed when all the following 4 criteria are fulfilled – i) fever, ii) hemorrhagic tendencies (positive tourniquet test, spontaneous bruising, bleeding from mucosa, gingiva, haematemesis, bleeding from injection sites etc), iii) thrombocytopenia (<100 000 platelets/mm³ or estimated as < 3 platelets per high-power field), and iv) evidence of plasma leakage (hematocrit 20% higher than expected or drop in hematocrit of 20% or more from baseline after intravenous fluid administration).¹⁰

Although the most common complications of dengue fever is fatigue, DHF is most dangerous of all. It can, not uncommonly, lead to bleeding and shock. The incidence of CNS involvement in dengue infection is low and ranges from 0.88% to 5.4% but the fatality rate is high. This encephalopathy may occur as a consequence of microcapillary hemorrhage leading to intracranial bleed, cerebral edema, hyponatremia, cerebral anoxia, and release of toxic products. Cardiac disturbances and reactive hepatitis have been reported during recent years.²

The most critical phase of this viral infection is the defervescent phase when the fever subsides but the patient develops life-threatening thrombocytopenia due to complement activation by viral antigens binding to platelets.

The mainstay of treatment is supportive therapy. Platelet transfusion is rarely indicated unless the level drops significantly or if there is significant bleeding. However, transfusion is recommended if platelet count falls below 20000/ml even without hemorrhage or approximately 50000/ml with hemorrhage. Surgical intervention for ocular and intracranial surgeries can be undertaken after correction of coagulation defect with platelet count above 100000/mL.¹

The most common hemorrhagic tendencies described in the literature are petechial hemorrhage, ecchymosis, gastrointestinal bleed, epistaxis, and others, but in our cases history of nasal bleed and petechiae were present only in two cases.⁵

This raises the concern whether the CNS is more prone to bleed than other sites. Altered sensorium in these patients may be wrongly attributed to shock, delirium, and fever. Any delay in diagnosis of ICH in these patients may be fatal. Timely operative intervention in five cases led to good recovery in spite of poor neurologic status before surgery, whereas cases 5 and 7 were managed conservatively but died because of deep seated bleed and late reporting to hospitals.

The exact mechanism of bleeding in DHF is not clear, but it seems to be multifactorial. Thrombocytopenia, prolonged prothrombin time, mild degree of disseminated intravascular coagulation, and hepatic dysfunction all seem to contribute synergistically.

Recent data do not advocate a delay in extubating patients when neurological impairment is the only reason for prolonged intubation. An appropriate choice of sedatives and analgesics during mechanical ventilation of neurosurgical patients allows for a narrower range of wake-up time, and weaning protocols incorporating respiratory and neurological measures may improve outcome.

Shivbalan et al.⁹ have observed that the spontaneous bleed was most commonly associated with deranged prothrombin time. A combination of (a) biphasic pattern of fever, (b) hemoconcentration, (c) platelet count less than 50000/mm³, and (d) elevated ALT had a sensitivity of 79.2%, specificity of 64.7% with a positive predictive value of 70%, and a negative predictive value of 75% in predicting spontaneous bleeding in dengue.

Tripathi et al.¹² observed hemorrhage in 2.5% of cases in their series. This included complications such as haematemesis (28%); epistaxis (27%); melena (14%); lymphadenopathy, especially cervical (31%); palatal

Meena et al

rashes (27%); and hepatomegaly (24%); but none had ICH. None of the patients in our series had such findings except major ICH. The reason for this fatal ICH in the absence of bleed from the other sites commonly described in literature is not known. This change in trends needs further careful observation and investigation.

Conclusion

A high degree of suspicion in dengue is required especially during convalescence in those patients who are disoriented and have altered sensorium. It should not be misinterpreted as fever delirium or toxic encephalopathy. It needs immediate attention and investigation. Timely diagnosis, adequate fluid management and intervention can thus save lives.

References

1. Ali N, Usman M, Syed N, Khurshid M. Haemorrhagic manifestations and utility of haematological parameters in dengue fever. A tertiary care centre experience at Karachi. **Scand J Infect Dis** 39:1025-1028, 2007
2. Angibaud G, Luaute J, Laille M. Brain involvement in dengue fever. **J Clin Neurosci** 8:63-65, 2001
3. Dar L, Gupta E, Narang P, Broor S. Cocirculation of Dengue Serotypes, Delhi, India, 2003. **Emerg Infect Dis** 12:352-353, 2006
4. Dengue haemorrhagic fever: Diagnosis, treatment, prevention and control. 2nd edition. Geneva: **WHO** 1-84, 1997
5. Gupta E, Dar L, Kapoor G, Broor S. The changing epidemiology of dengue in Delhi, India. **Viol J** 3:92, 2006
6. Halstead SB, Heinz FX, Barrett AD, Roehrig JT. Dengue virus: molecular basis of cell entry and pathogenesis, 25-27 June 2003, Vienna, Austria. **Vaccine** 23:849-856, 2005
7. Imported dengue - Florida, 1997-1998. **Can Commun Dis Rep** 26:77-79, 2000
8. Rothman AL, Ennis FA. Immunopathogenesis of dengue hemorrhagic fever. **Virology** 257:1-6, 1999
9. Shivbalan S, Anandnathan K, Balasubramanian S, Datta M, Amalraj E. Predictors of spontaneous bleeding in dengue. **Indian J Pediatr** 71:33-36, 2004
10. Shu PY, Huang JH. Current advances in dengue diagnosis. **Clin Diagn Lab Immunol** 11:642-650, 2004
11. Solomon T, Dung NM, Vaughn DW, Kneen R, Thao LT, Raengsakulrach B, et al. Neurological manifestations of dengue infection. **Lancet** 355:1053-1059, 2000
12. Tripathi BK, Gupta B, Sinha RS, Prasad S, Sharma DK. Experience in adult population in dengue outbreak in Delhi. **J Assoc Physicians India** 46:273-276, 1998
13. Whitehead SS, Blaney JE, Durbin AP, Murphy BR. Prospects for a dengue virus vaccine. **Nat Rev Microbiol** 5:518-528, 2007